

# Periodontal Health in Oklahoma

Oklahoma Center for  
Implants & Periodontics

## Our Mission Statement

Changing the Lives of  
Patients

Our office changes the lives of people through premiere service and the highest quality of implant and periodontal treatment offered today.

Robin D. Henderson, D.M.D.,  
M.S.

Diplomate of the American  
Board of Periodontology

Emphasis on Comprehensive  
Periodontics, Soft Tissue  
Grafting, and Dental Implants

## In This Issue

Relieve Frenum Tension

New Team Member  
Highlight - Chris Poore,  
DDs, MS

Hygiene Expo Update

Ask Dr. Henderson

Comments From Noel  
Kelsch, RDH

## Contact Us:

3330 NW 56th Street  
Suite 110  
Oklahoma City, OK 73112

(405) 947-0486  
(405) 942-4392 FAX

[www.OkPerioImplant.com](http://www.OkPerioImplant.com)

Editor:  
Dawn Wilson, RDH, BA  
[tdwilson@prodigy.net](mailto:tdwilson@prodigy.net)

Volume 1 Issue 7

Summer 2009

## Relieve Frenum Tension

Treating frenum issues can be tricky. Sometimes a frenectomy is all that is needed to fix the problem, other times soft tissue grafting must be done. Diagnosis is very important in these situations because the requirements for each procedure vary.

A frenectomy is performed to release the tension that pulls the gingival tissues. When a frenum is attached at the gingival margin, it needs to be released because the constant tug creates gingival recession. If the frenum is not attached at the gingival margin, then it may not need to be released.

Soft tissue grafting procedures are done

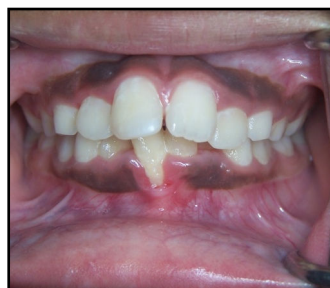

Figure 1:  
Perfect case  
when a frenec-  
tomy and a  
soft tissue  
graft should  
have been  
done.

for various tissue conditions; in the case of frenum issues a soft tissue graft is necessary because the thin tissue cannot withstand normal daily forces.

Figure 1 is a great example of why frenectomies should be done. This young patient experienced severe trauma from a high frenum. A soft tissue graft is necessary to stabilize this area due to the high frenum and inadequate zone of attached gingiva.

When the tissue is very thin and fragile, it does not have enough strength to handle normal brushing or mastication and will break down and recede, see Figure 2. Grafting treats and prevents recession defects but once recession occurs, it must be addressed. Recession should be treated as a form of periodontal disease. Although, it is not always bacteria induced, there is

*Continued on Page 2*



Robin D. Henderson, DMD, MS


## Welcome Our New Team Member - Dr. Chris Poore

I constantly strive to give my patients the most up to date care possible. For this reason, we are pleased to announce an expansion in our dental team that allows us to continue providing optimum care for our patients.

**Dr. Chris Poore** joined our office this summer in hopes to contribute to the practice philosophies. Born just outside of Chicago, Illinois he moved to the Tulsa/Broken Arrow area at a young age. He maintains that

he has been here long enough to be considered an Oklahoman. After high school Dr. Poore attended Oklahoma State University with hopes of becoming a veterinarian.

However, a part time job as a dental assistant in Stillwater changed his career path, at that point he knew dentistry was in his future.



Chris Poore, DDS, MS

*Continued on Page 3*

## Cont...Frenum Tension

attachment loss which leads to further bone loss and eventually tooth loss.

When a frenum is attached at the gingival margin and recession has occurred, or when the tissue is thin and fragile, even if the frenum was removed, it is necessary for a soft tissue grafting procedure to be done to reinforce the tissue thickness. This treats and prevents recession from continuing.

Many times a high frenum position can be treated by releasing the tension associated with the frenum with just a soft tissue graft. Performing the procedures at the same time is easier and less expensive for the patient. Sometimes a frenectomy is done first and then a soft tissue graft at a secondary, separate appointment depending on the surgical needs.

Regardless of the technique, frenums need to be carefully monitored for changes over time. More importantly, the tissue thickness should be identified so procedures can be done sooner and prevent future breakdown and recession, see figure 3.

Figure 4 is a prime example of needing a simple frenectomy on the maxil-

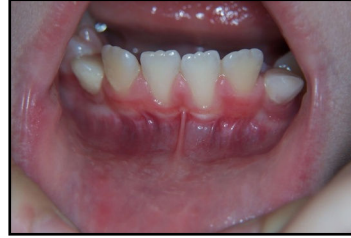

Figure 2: Could do separate procedures or at the same time and save the patient some pain and money.

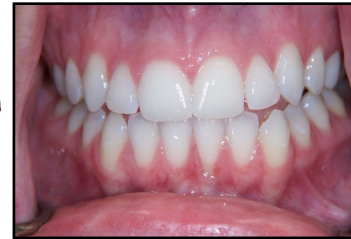

Figure 3: Recession, inadequate zones of attached gingiva, and heavy tension. Requires a combination of procedures done at different times.

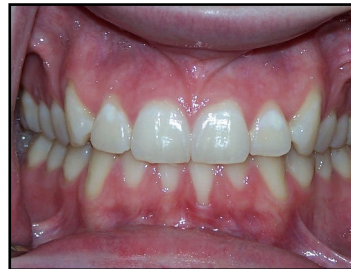

Figure 4: Maxillary frenum too close to incisive papilla. If not released, irreparable interproximal recession.

lary anterior due to the position of the frenum and the proximity to the incisive papilla. Without removal, this area will experience irreparable interproximal recession.

Looking at the mandibular anterior, there is recession as well as evidence of frenal pull. The tissues are thin and need soft tissue grafting procedures. The recession and thin tissues on the canines will need treatment later.

Frenectomies and soft tissue grafts are very important and somewhat simple procedures. It is important to discover the issues early before any damage is done. Not identifying or intervening early can mean more costly and more difficult procedures later. Hygienists are in a great position to detect these issues and refer for treatment.



Send your questions to Robin,  
Robin@OkPerioImplant.com

### Ask Dr. Henderson...

Q: What is the best way for a patient to control root sensitivity following SRP?

A: Fluoride is the best way. It is important to remineralize the root surface and occlude the dentinal tubules to obstruct fluid exchange which causes sensitivity problems. Different types of fluorides and products work differently for each patient, sometimes it is trial and error to find the right one.

Q: Why are the lingual of the lower anterior last affected by the damage pattern of meth use? Answer: Noel Kelsch, RDH

A: We really do not know yet. The pattern is apparent but this issue has not been studied. It is hypothesized that because that area tends to stay dry when the patient is breathing through the mouth and has severe xerostomia.

The bathing of the teeth with saliva that is very acidic is thought to create the decay pattern. It is also hypothesized that is why a cuspid can have severe decay on the entire tooth except the tip of the cusp. The decayed area is constantly being bathed with saliva that is extremely acidic and the tip is free from the exposure.


## Cont...Dr. Chris Poore

After graduating with honors from OSU with a bachelor's degree in Biology, Dr. Poore attended dental school at the University of Oklahoma and just completed three years of additional training in the specialty of Periodontics.

Dr. Poore currently resides in Edmond with his beautiful wife of three years. Together they are the proud parents of a 1 year old baby girl, who's first word by the way, was "papa." He believes he holds the world record for the shortest amount of time taken to become wrapped around a daughter's finger. Even though they currently have only one child, the Poore's stay pretty busy. They have three rescued dogs and two orange cats which keep them on their toes.

In his free time, Dr. Poore enjoys spending time with the family, starting home projects (usually not finishing them in the planned time), and outdoor sports.

Dr. Poore considers himself to be a well rounded clinician, but has a special interest in implant dentistry and complex soft tissue procedures. However, he is always up for a good old fashioned round of aggressive scaling and root planing.



Dr. Kesa McConnell, Kinley and Dr. Chris Poore

We continue to specialize in conservative treatment of gum disease with an emphasis on comprehensive periodontics, soft tissue grafting and dental implants. Our commitment is to improve the foundation of our patient's smile and having Dr. Poore join our team should prove to be valuable so we may continue that commitment.

### A Note from Guest Speaker, Noel Kelsch, RDH

What a wonderful month it has been. SOO full that I have not had ten minutes to catch my breathe! I really wanted to tell you how much the seminar meant to so many. Thank you so much for inviting me.

I have spent a large amount of time since the seminar getting services for several people (your state is not exactly set up for intervention). We have now had 9 interventions as a result of the seminar. There are some lives that will never be the same again after attending that course.

Thank you all for allowing me to be a part of that change.

It is so funny I, of course, thought that everyone was upset at the computer crashing. Last week when I talked to one of the audience members I apologized for the computer glitch. She said what computer glitch? I thought you did that on purpose! She said, "that day saved my sons life."

Isn't amazing what we get to do? I am still taken back by the number of emails I received from that day and the thank yous that have come from giving those simple tools. Thank you again for giving me a venue to share.

*Love and blessings Noel , 6/15/09*



### Second Annual Hygiene Expo, A Great Success

*From the Editor...*

After last year's successful Hygiene Expo, we were anxious to host another great meeting but we could not have imagined the response we received. On May 1, all records were broken when registration nearly doubled from last year to almost 350 hygienists from all over Oklahoma. The event was held in Oklahoma City at the Cox Convention Center with twice as many vendors, massage therapists, door prizes and of course, informative continuing education courses.

Our featured morning speaker Noel Kelsch, RDH discussed Meth Mouth and Other Dental Care Considerations. Many attendees appreciated the "new topic" but especially the speaker's enthusiasm and passion. Written survey responses were very positive stating, "Noel was great, very easy to listen to!", "an eye-opening experience" re-

garding the effects of meth not only physically but also emotionally. She captivated the audience with her personal stories which she intertwined with pertinent clinical information the participants could apply at home or in their practice.

In the morning session and during lunch prizes upon prizes were given away. Prizes ranged from \$10 gift cards to tickets to *The Lion King* and the grand prize a new 26" plasma television. Congratulations Brenda B. for winning the TV!

In the afternoon session, Dr. Henderson had the opportunity to shed a little more light on the Perio Protect Method and why it is so important. While many hygienists have seen the ads in



Oklahoma Center for Implants & Periodontics  
3330 NW 56th St., Ste. 110  
Oklahoma City, OK 73112  
E-mail: [Robin@OkPerioImplant.com](mailto:Robin@OkPerioImplant.com)

My mission is to give the most accurate information available about Dental Health. Unfortunately, there is a lot of misinformation out there and I would like to set the record straight. We are Committed to improving the foundation of a patient's smile.

I would like to be able to answer your questions and perhaps share some of my observations I see on a daily basis through this newsletter or online. It doesn't have to be all business, hopefully we can have some fun too.

Check us out: [www.okperioimplant.blogspot.com](http://www.okperioimplant.blogspot.com)

Name

Address

City, State Zip

Committed to improving the  
foundation of a patient's smile.

## Cont... Hygiene Expo A Great Success

magazines and on TV, not many were familiar with how it will change the way we treat periodontal patients today. Many hygienists left thankful feeling they were armed with "new" information they could use.

As always, Dr. Henderson wants to bring dental hygienists, his "favorite people", together for an informative and fun day to reconnect with colleagues or perhaps meet new ones. Our intent is to give you a forum through the hygiene expo, newsletter and website focused on what is important to you and your practice. Your feedback is pertinent so we can continue providing you with valuable information.

We still had to turn some away this year so we are in search of a new venue to accommodate a bigger Expo for next spring. If you attended this year's Hygiene Expo, be on the lookout for a special 'invitation only' CE this fall.

All survey feedback is taken into consideration, thanks to those who let us know what we are doing right and how we can do better. We appreciate your support.

Many participants responded to the question "What was the best part of this meeting?"

Here are a few of the responses:

"The presenters Dr. Henderson chose for the 2 Spring Flings. Exceptional."

"You always do above and beyond. I appreciate it so much."

"I enjoyed the whole seminar. Well balanced. Breakfast and lunch were appreciated."

"Everything, you guys do a great job! Thank you for always having wonderful, new information."

"Comfortable, easy going atmosphere - non-threatening."

"Inexpensive good CE, seeing hygiene friends, feeling like we had been "treated" to a great day from Dr. RDH."

"Won a Door Prize. Great Idea."

"It opened my eyes. I was ignorant about meth."

"Loved hygiene oriented vendors & the Massage:)"

"All of It."

"Everything! Great meeting, meal, and speakers. Looking forward to next year."

